

ROLE OF PROPRIOCEPTIVE AFFERENTS IN REGULATION OF RESPIRATORY ACTIVITY IN DOG

By

A.P. SHARMA

From the Department of Physiology, All India Institute of Medical Sciences, New Delhi

(Received April 4, 1962)

The role of proprioceptive afferents from the respiratory muscles, bones and joints in reflex control of respiratory activity in dial-anaesthetised dogs was studied. It was seen that step by step removal of thoraco-cervical afferents, excluding the exteroceptive ones, led to increased respiratory activity, the effect being temporary when vagi were in tact and persistent in vagotomised animal. After resection of all the thoracocervical posterior nerve roots in the animal with intact vagi, respiratory rate and depth were however greatly reduced. Bilateral vagotomy following such a resection and conversely such a resection following double vagotomy, both led to respiratory failure almost immediately. The suggestion is made that the proprioceptive afferents in the thoracocervical nerve roots exert a restraining effect and are necessary for proper maintenance of rhythmic respiratory activity, in conjunction with vagal pulmonary afferents.

Literature is rich in studies pertaining to the reflex control of respiratory activity through sensory messages arising from the various reflexogenic areas in the lung, heart and the larger blood vessels (Aviado and Schmidt, 1955; Paintal, 1955, 1957; Wang and Wang, 1959). So far, the principles of centrifugal control of sensory messages, so well established in muscle and some special sense organs, has received little explicit attention in the proprioceptive control of respiration. The importance of afferent impulses from limb muscles and joints in the extra-pulmonary regulation of respiratory activity has been recognised and brought to light in reviews by Gardner (1950) and Bjurstedt (1957). Bailen and Horvath (1959) have summarised the factors responsible for the integration of respiratory minute volume to the metabolic needs of the body. Important respiratory effects of proprioceptive impulses from lower jaw and limb muscles and joints have been reported by Sharma and Sharma (1958), and Sharma (1960).

Since the respiratory act is brought about by the regular and co-ordinated contraction and relaxation of a large number of skeletal muscles attached to the thoracic cage including the diaphragmatic musculature, it appears very likely that proprioceptive impulses from these respiratory muscles and joints should play an important role in the reflex control of respiratory activity. The present study has been carried out to test this assumption.

METHODS

The study has been carried out in dogs of either sex weighing between 8 to 12 kg and anaesthetized with dial (0.05 g per kg body weight) administered intraperitoneally. Tracheal respiration was kymographically recorded after performing tracheotomy and connecting the tracheal tube to a recording tambour. Time has been marked at 5-sec intervals. A rectal thermometer indicated the body temperature which was maintained at 38°C.

The two vagi were exposed in the neck and threaded. The dog was then shifted to the prone position and a long dorsal mid-line incision extending from the base of the skull to the mid-lumbar region, was made. The skin flaps along with the subcutaneous connective tissue layers were reflected laterally and separated completely from the deeper muscular layers severing all nervous connections, right upto the mid-ventral line on both sides. Thus the skin in the cervical, thoracic and upper lumbar regions including that of the upper limbs, was completely denervated and excised, serving only to wrap the animal in its folds to prevent excessive heat loss. Next, a dorsal laminectomy was performed bit by bit and the spinal cord surrounded by its sheaths was exposed in the vertebral canal, from the mid-lumbar to the first cervical segment. Caution was necessary while exposing the spinal cord at the level of 4th and 5th cervical vertebrae as slightest traction on the cord here led to an immediate cardiac arrest though the respiration continued for a short while more.

The dorsal spinal nerve roots in the thoracic and cervical regions on both the sides were gently lifted up and threads passed below them so that they could be quickly resected when required.

In about 15 to 30 min the respiration became stable and regular. The blood pressure remained at 20 to 40 mm of Hg and was well sustained. The dorsal spinal roots were resected in steps and the effect of successive resections on respiration was observed. Finally the two vagi were cut and the respiratory effects recorded.

In the next series of experiments the order was reversed. Vagotomy was performed first and subsequently the spinal dorsal root resection was done and the corresponding respiratory effects observed.

RESULTS

Fourteen experiments were performed. In the dog with both vagi intact and the skin in the cervical, thoracic, upper lumbar and upper limb regions

resected, the bilateral section of the dorsal spinal nerve roots in the thoracic segments resulted in an immediate augmentation of depth and acceleration of the rate of respiration. The increase in respiratory activity persisted for a few minutes (1-5 min) and then gradually wore off. Restoration was usually complete (Fig. 1, A).

Following on the above, bilateral section of the dorsal spinal nerve roots of the lower cervical segments (C 5, 6, 7 and 8) also, resulted in a similar and more marked augmentation and acceleration of respiratory activity. The effect was again short lived and gradually passed away though some residual effect might be left behind. Sectioning of the remaining of the cervical roots also produced a similar increase in respiratory activity through to a varying extent, which effect was however less marked and was replaced by a much greater fall in respiratory activity, depth and rate both being greatly reduced. Stabilisation occurred at a low level (Fig. 1, B and C).

If either of the two vagi was sectioned, the respiratory activity was not much altered. But as soon as the other vagus was also sectioned, respiratory activity, after one or two more breaths, stopped completely and could not be revived (Fig. 1, D).

When at the beginning of the experiment, both vagi were cut at the level of the root of the neck, respiration became slow and deep. Subsequent bilateral resection of the thoracic and the lower cervical posterior nerve roots individually produced an increase in respiratory activity, which was much more powerful and persistent than in the animal with intact vagi. Both the rate and depth of respiration (even though the latter was already increased due to vagal section) were increased to a very great extent. There was little attempt at restoration and major part of the effect was persistent in marked contrast to the animal with intact vagi in which restoration was more or less complete (Fig. 2, A, C and D).

However, the ultimate resection of the remaining upper cervical nerve roots, led to respiratory failure. A few quick and deep gasps heralded the failure. The gasps then came at successively longer intervals and finally ceased altogether (Fig. 2, E).

Splitting of the duramater and opening up of the subdural space did not alter respiratory activity (Fig. 2, B).

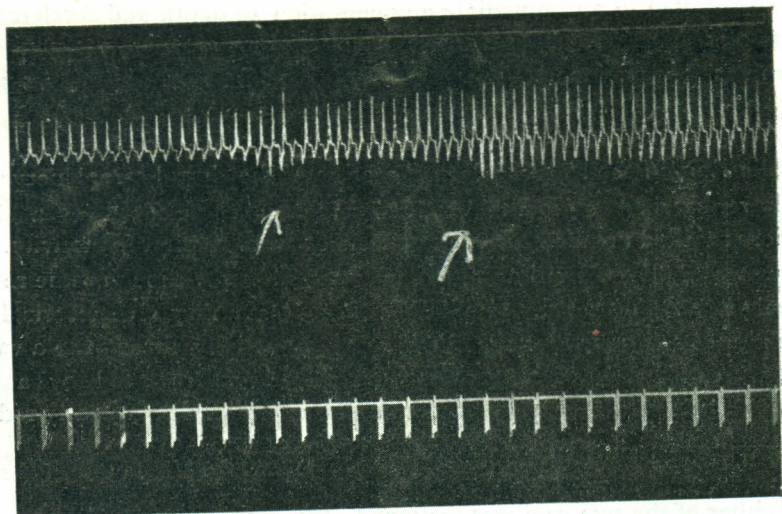


Fig. 1. A,

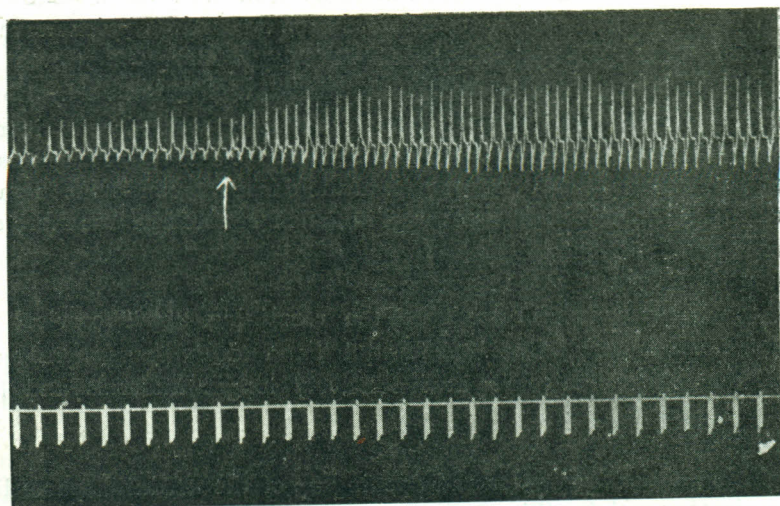


Fig. 1. B.

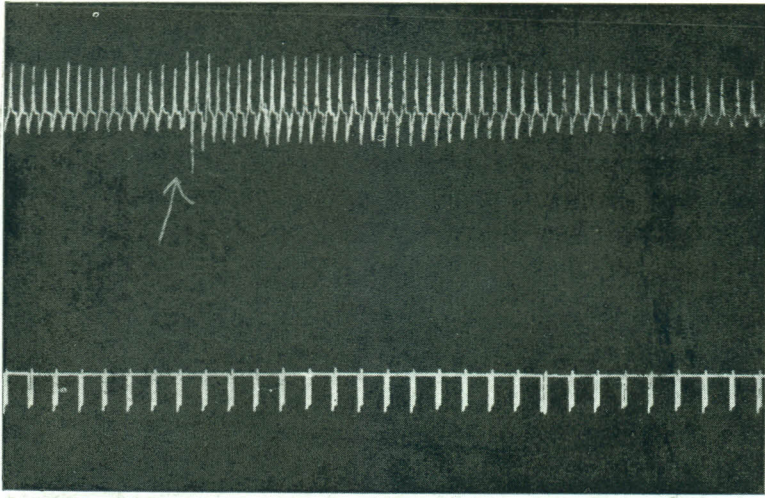


Fig. 1. C.

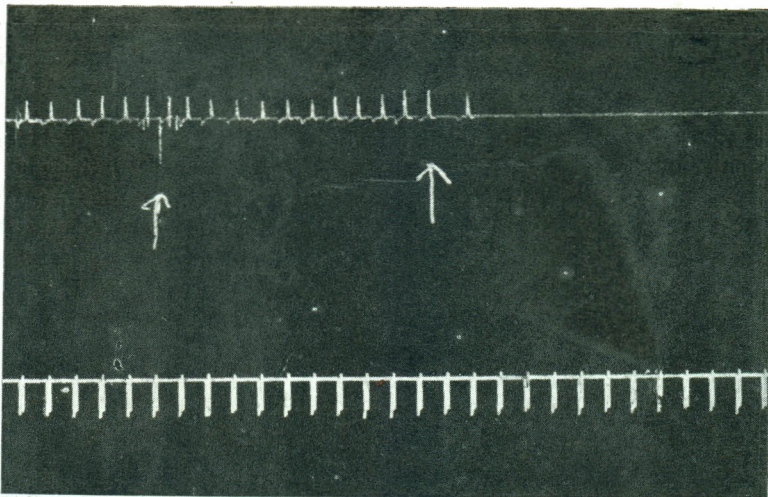


Fig. 1. D.

Dial-anaesthetised dog. Effect on respiration in respective sequence, of bilateral resection of (A) lower (first arrow) and upper (second arrow) thoracic dorsal spinal nerve roots, (B) lower and (C) upper cervical posterior nerve roots, and (D) right (first arrow) and left (second arrow) vagus nerves. Time in 5 sec.

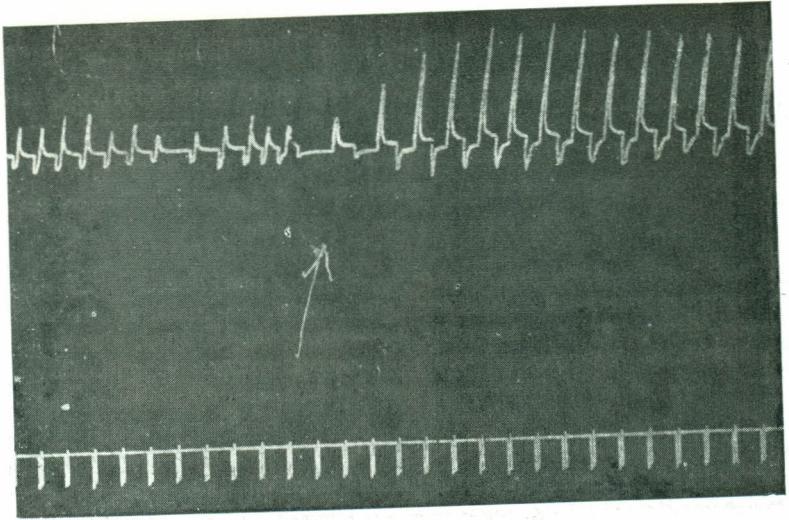


Fig. 2. A.

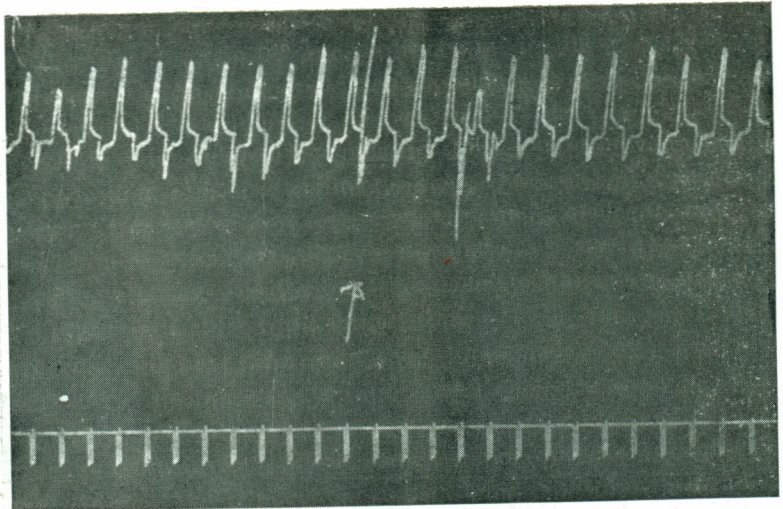


Fig. 2. B.

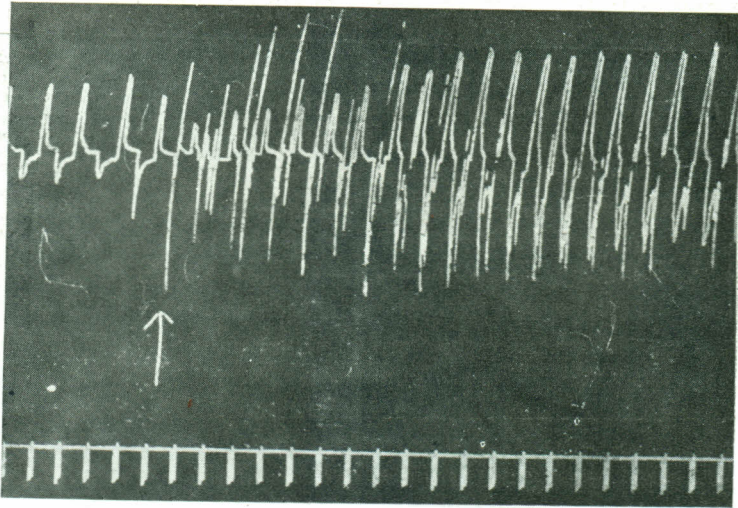


Fig. 2. C.

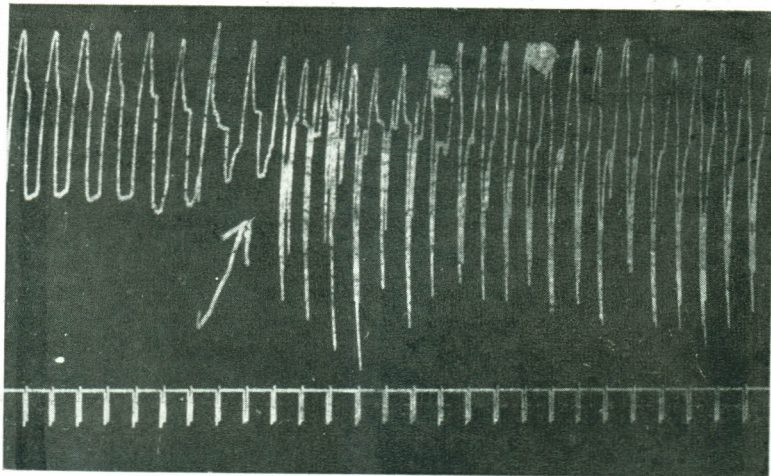


Fig. 2. D.

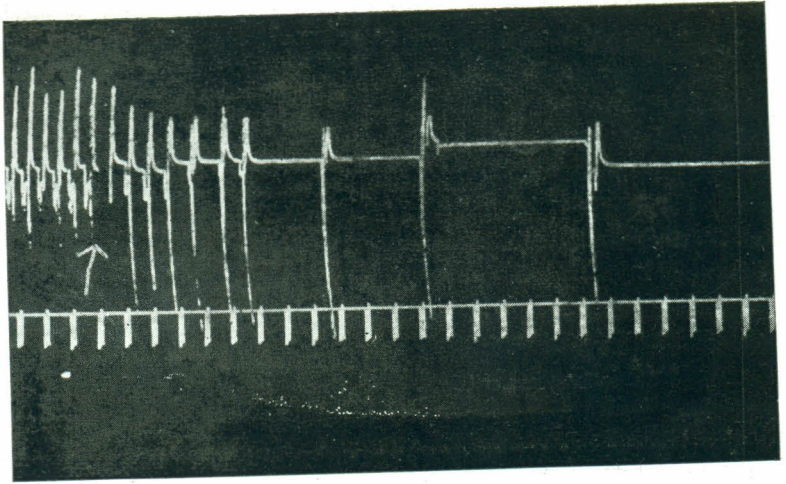


Fig. 2. E.

Dial-anaesthetised dog. Effect on respiration in respective sequence, of (A) bilateral vagotomy, (B) incision of dura mata, (C) bilateral resection of thoracic posterior nerve roots, (D) lower cervical nerve roots, and (E) upper cervical nerve roots. Time in 5 sec.

DISCUSSION

Removal of thoracic and cervical afferents by sectioning dorsal nerve roots greatly modified the respiratory activity in dog. The skin, along with the deeper subcutaneous tissues, in the upper lumbar, thoracic and cervical regions (including the upper limbs) were denervated prior to nerve root resection. The exteroceptive afferents were thereby excluded from being involved in the production of the above results. Only the proprioceptive and the viscerosensitive afferents were left behind. Of the visceral afferents, a great majority from the thoracic and cervical viscera (chiefly the lungs and the heart), traveled via the vagus and the glossopharyngeal nerves. Therefore, the respiratory effects observed on sectioning the thoracic and the cervical nerve roots would be mainly due to interference with the inflow of proprioceptive afferents and only to a minor extent to that of visceral afferents i.e. those travelling along sympathetic afferent pathways.

Removal of thoraco-cervical afferents at each successive step was seen to produce an acceleration and/or augmentation of respiratory activity. Such effects passed away after a few minutes if the two vagi were intact, and persisted more or less undiminished or only slightly diminished in the vagotomized animal. This would mean that these spinal afferents exerted a restraining influence over respiratory activity and that this influence could be compensated by vagal influence. When this restraint was removed, the result was acceleration and/or augmentation of respiratory activity. That led to more vagal afferents which brought down the increased respiratory activity. However with the vagi intact, the removal of the last consignment of the thoraco-cervical afferents was followed, after a shortlived increase, by a permanent and marked fall in the rate and depth of respiration. With prior bilateral vagotomy the same procedure was followed by a complete cessation of respiratory activity after a few gasps. A succeeding vagotomy in the former instance as well, resulted in cessation of respiration after a few more breaths. Obviously it would suggest that the cervical and thoracic spinal afferents on the one hand and the vagal afferents on the other, provided a driving force for rhythmic respiratory activity. In the complete absence of either, rhythmic respiration would be maintained by the other though at a lower level. When both were gone, respiration was also gone. For normal respiratory activity both appeared to work in close collaboration. Since the lumbo-sacral spinal afferents were still intact when respiration stopped due to removal of thoracocervical and vagal afferents, lumbo-sacral afferents by themselves did not appear to be able to maintain rhythmic respiratory activity.

The occurrence of a few respirations before the respiratory activity was brought to a standstill by removing vagal and thoraco-cervical spinal afferents, indicated an unsuccessful attempt on the part of the respiratory centre unaided by vagal or spinal afferent drive, to maintain rhythmic respiratory activity. Wang *et al.* (1957), have shown that isolated medulla would maintain rhythmic respiration without the influence of spinal or vagal afferents, but only under special conditions. The inability of the medullary and other respiratory centres to maintain rhythmic respiratory activity after removal of the vagal and cervico-thoracic spinal afferents in our experiments, might be due to the effect of anaesthesia or even low blood pressure under which conditions medullary activity could be greatly modified. They also suggest that in normal respiration the rhythm originates in the pontile apneustic centre with periodic modulations by inhibitory impulses from pulmonary stretch receptors in the vagus and from the pneumotaxic centre in the rostral pons. It is suggested that proprioceptive afferents from the respiratory muscles, bones and joints also have an important role in regulation of respiratory activity. In common with skeletal muscular activity in general, the proprioceptive afferents from the respiratory muscles and joints, are essential for proper respiratory function. These afferents in some respects are at par with pulmonary afferents carried in the vagi and together with them, nearly indispensable for respiratory activity.

REFERENCES

- Aviado, D.M. and Schmidt, C.F. (1955). *Physiol. Rev.*, **35**, 247.
Bailen, H.N. and Horvath, S.M. (1959). *Am. J. Physiol.*, **196**, 467.
Bjurstedt, H. (1957). *Annual Rev. Physiol.*, **19**, 151.
Gardner, E. (1950). *Physiol. Rev.*, **30**, 127.
Paintal, A.S. (1955). *Quart. J. Exptl. Physiol.*, **40**, 89.
Paintal, A.S. (1957). *Quart. J. Exptl. Physiol.*, **42**, 56.
Sharma, A.P. and Sharma, O.P. (1958). *Ind. Jour. Med. Res.*, **46**, 770.
Sharma, A.F. (1950). *Ind. Jour. Med. Res.*, **48**, 439.
Wang, Hsueh-Hwa and Wang, S.C. (1959). *Annual Rev. Physiol.*, **21**, 151.
Wang, S.C., Ngai, S.H. and Frumin, M.J. (1957). *Am. J. Physiol.*, **190**, 333.
-